

Bilateral Extensive Papillomacular Myelination of Retinal Nerve Fibers: A Case Report

Dear Editor,

Myelinated retinal nerve fiber (MRNF) layers appear as white or gray-white patches on the surface of the retina with feathery margins correspond to the distribution of ganglion cell axons [1]. It is an uncommon benign developmental anomaly in 0.4% to 1% of the population, with a bilateral involvement rate of about 7% [2]. Patients are mostly asymptomatic, but visual function can be affected depending on the extent, location of the MRNF and coexisting ocular abnormalities. Here, we report a rare case of extensive MRNF involving the papillomacular bundles in both eyes.

A 22-year-old female presented to our clinic with complaints of nystagmus and decreased vision. She had no systemic co-morbidities and family history of ocular disease. Her best-corrected visual acuities were 20 / 100 in both eyes, and refraction values were -5.50 / -5.00 × 175 in the right eye and -7.00 / -3.50 × 10 in the left eye. The anterior segment was unremarkable, and intraocular pressure were 19 mmHg in the right eye, and 21 mmHg in the left eye. Fundus examination revealed extensive white striated patches consistent with MRNF along the papillomacular bundle in both eyes. Lesions of macular atrophy temporal to fovea were also observed (Fig. 1A, 1B), but there was no peripheral retinal abnormality in both eyes. On fundus autofluorescence, round hypo-autofluorescent lesions with hyper-autofluorescent borders on their superior, inferior, and temporal sides were observed at the region corresponding to the macular atrophic lesion temporal to fovea. In addition, other hypo-autofluorescent lesions nasal to fovea, which were separated from temporal atrophic lesions by normal autofluorescence at the fovea and were partially

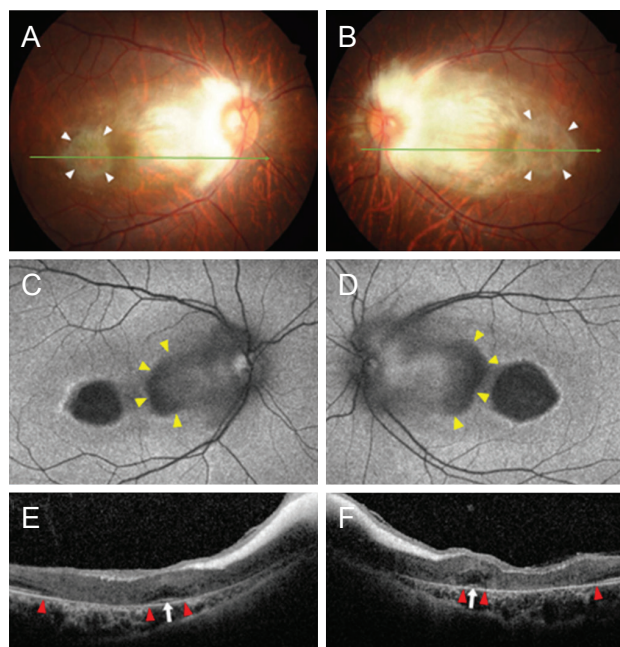


Fig. 1. Images of myelinated retinal nerve fibers (MRNFs) of both eyes of a patient. (A,B) Fundus photographs of both eyes show MRNFs involving the papillomacular bundle extensively. Note the retinal atrophic lesions temporal to the fovea (white arrowheads). (C,D) Fundus autofluorescent images of both eyes show round hypo-autofluorescent lesions at the region corresponding to the retinal atrophic lesion temporal to the fovea. Additional hypo-autofluorescent lesions separated from temporal atrophic lesions by normal autofluorescence at the fovea are observed nasal to the fovea (yellow arrowheads), but they are partially obscured by the MRNF. (E,F) Optical coherence tomography of both eyes shows MRNFs as hyper-reflective layers with tapered edges extending temporal to the fovea. Note the atrophic changes of the outer retina sparing the fovea (white arrows). Boundaries of macula atrophy lesions are indicated with red arrowheads. Informed consent for publication of the clinical images was obtained from the patient.

observed by the MRNF, were observed (Fig. 1C, 1D). On optical coherence tomography (OCT), MRNF appeared as a hyper-reflective layer with tapered edges extending temporal to fovea. The retinal layer structures of the macula underneath the MRNF were atrophic and replaced by homogenous tissue with moderate reflectivity, except at the fovea where outer nuclear layer and hyper-reflective lines of the ellipsoid zone were preserved (Fig. 1E, 1F). In the electroretinography, scotopic response was normal but photopic response was moderately decreased in both eyes.

Received: May 3, 2021 Final revision: July 16, 2021
Accepted: July 16, 2021

© 2021 The Korean Ophthalmological Society

This is an Open Access article distributed under the terms of the Creative Commons Attribution Non-Commercial License (<http://creativecommons.org/licenses/by-nc/3.0/>) which permits unrestricted non-commercial use, distribution, and reproduction in any medium, provided the original work is properly cited.

Myelination of optic nerve normally starts at lateral geniculate body and stops posterior to the lamina cribrosa. Oligodendrocytes play an important role in myelination, by proliferation and production of myelin under the influence of hormonal signals during the prenatal period. At lamina cribrosa, the myelination can cease owing to dense astrocytes, which may act as physical barriers. The physiology of MRNF formation has not been fully understood, but it is considered as an abnormal extension of myelination into the retinal nerve fiber layer beyond the lamina cribrosa. It may be due to abnormal migration of oligodendrocytes into the retina either before formation of barrier function of lamina cribrosa or through acquired disruption of lamina cribrosa. Thus, location of the MRNF is usually juxtatapillary and posterior to the equator [3].

The common ocular abnormalities associated with MRNF include anisometric myopia, amblyopia, and strabismus. In particular, widespread extension of MRNF has been reported to be associated with high myopia [4]. In this case involving extensive papillomacular MRNF in both eyes, high degrees myopia and nystagmus were observed. Although no other coexisting abnormalities were found in this case, a variety of abnormalities, such as craniofacial abnormalities, colobomas, neurofibromatosis, optic nerve hypoplasia have been reported to be associated with MRNFs [2].

Until now, only single report by Ong et al. [5] described bilateral extensive MRNF with papillomacular involvement. In the case, a fundus photograph showed macular atrophic lesions not only temporal but also nasal to fovea, which were obscured by MRNF. This finding is strikingly similar to the finding of the present case, suggesting that extensive MRNFs with papillomacular involvement may be accompanied by macular atrophy, unlike MRNFs of small sizes or those at other retinal locations. Based on spectral domain OCT and fundus autofluorescence, macular atrophy and outer retinal disruption sparing the fovea were confirmed in this case. However, the mechanisms for the atrophic change and foveal preservation are unclear

and need to be elucidated.

In conclusion, extensive involvement of bilateral papillomacular bundles by MRNF is a rare condition, and macular atrophy sparing the fovea may be accompanied. Imaging modalities, including fundus autofluorescence and spectral domain OCT, may be helpful to reveal structural changes of the macula obscured by MRNF.

Chae Hyun Song, Un Chul Park

*Department of Ophthalmology, Seoul National University
College of Medicine, Seoul, Korea
E-mail (Un Chul Park): ucpark@snu.ac.kr*

Conflict of Interest

No potential conflict of interest relevant to this article was reported.

References

1. Shelton JB, Digre KB, Gilman J, et al. Characteristics of myelinated retinal nerve fiber layer in ophthalmic imaging: findings on autofluorescence, fluorescein angiographic, infrared, optical coherence tomographic, and red-free images. *JAMA Ophthalmol* 2013;131:107-9.
2. Tarabishy AB, Alexandrou TJ, Traboulsi EI. Syndrome of myelinated retinal nerve fibers, myopia, and amblyopia: a review. *Surv Ophthalmol* 2007;52:588-96.
3. Rao R, Turkoglu EB, Say E, Shields CL. Clinical features, imaging, and natural history of myelinated retinal nerve fiber layer. *Retina* 2019;39:1125-32.
4. Straatsma BR, Heckenlively JR, Foos RY, Shahinian JK. Myelinated retinal nerve fibers associated with ipsilateral myopia, amblyopia, and strabismus. *Am J Ophthalmol* 1979;88(3 Pt 1):506-10.
5. Ong JM, Poornesh KN, El-Hindy N, Goble R. Bilateral macular atrophy and papillomacular myelinated nerve fibre. *J Paediatr Child Health* 2011;47:67-8.