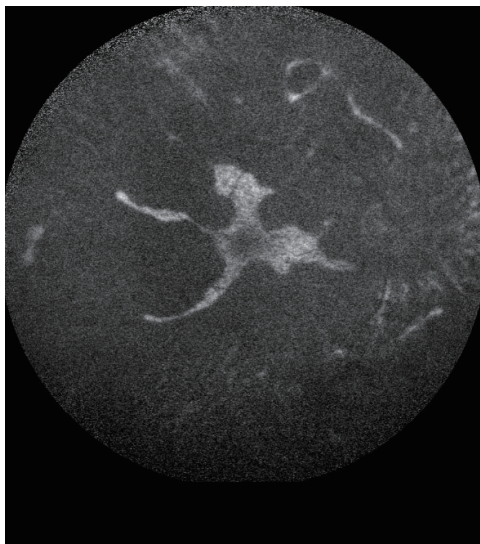
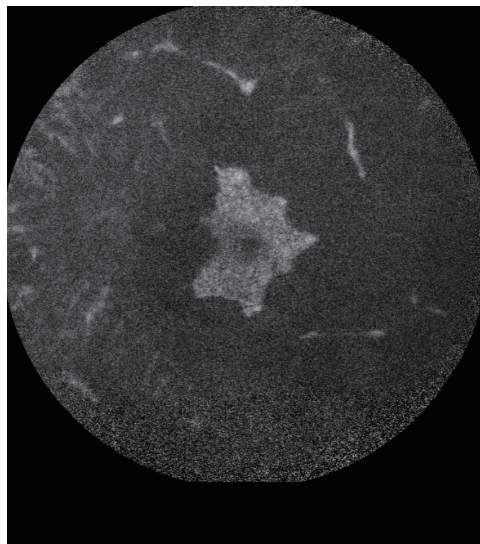
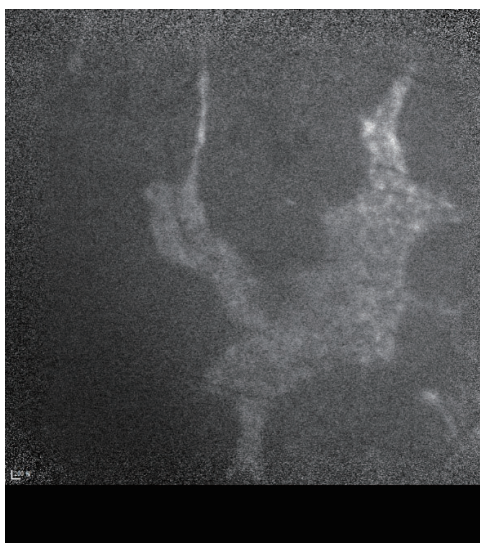
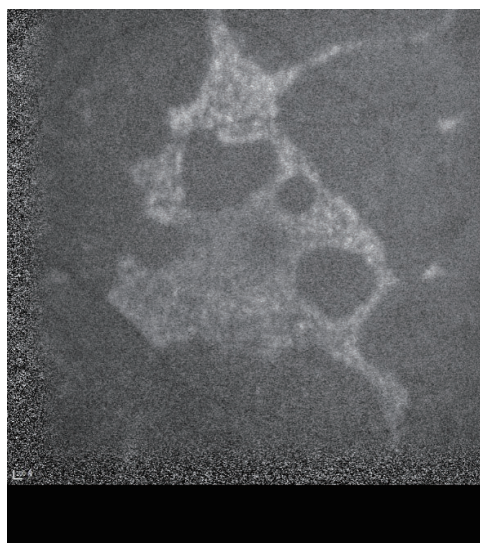
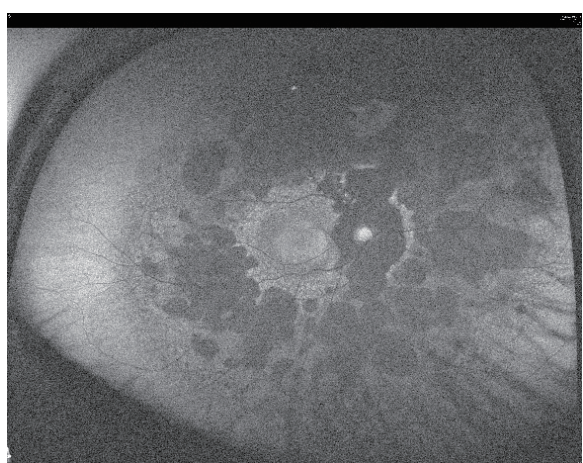
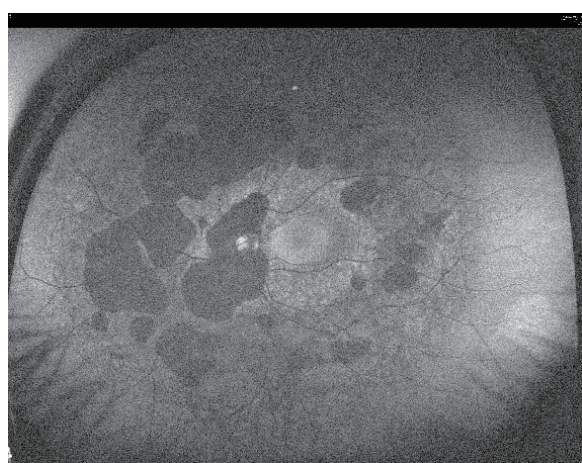
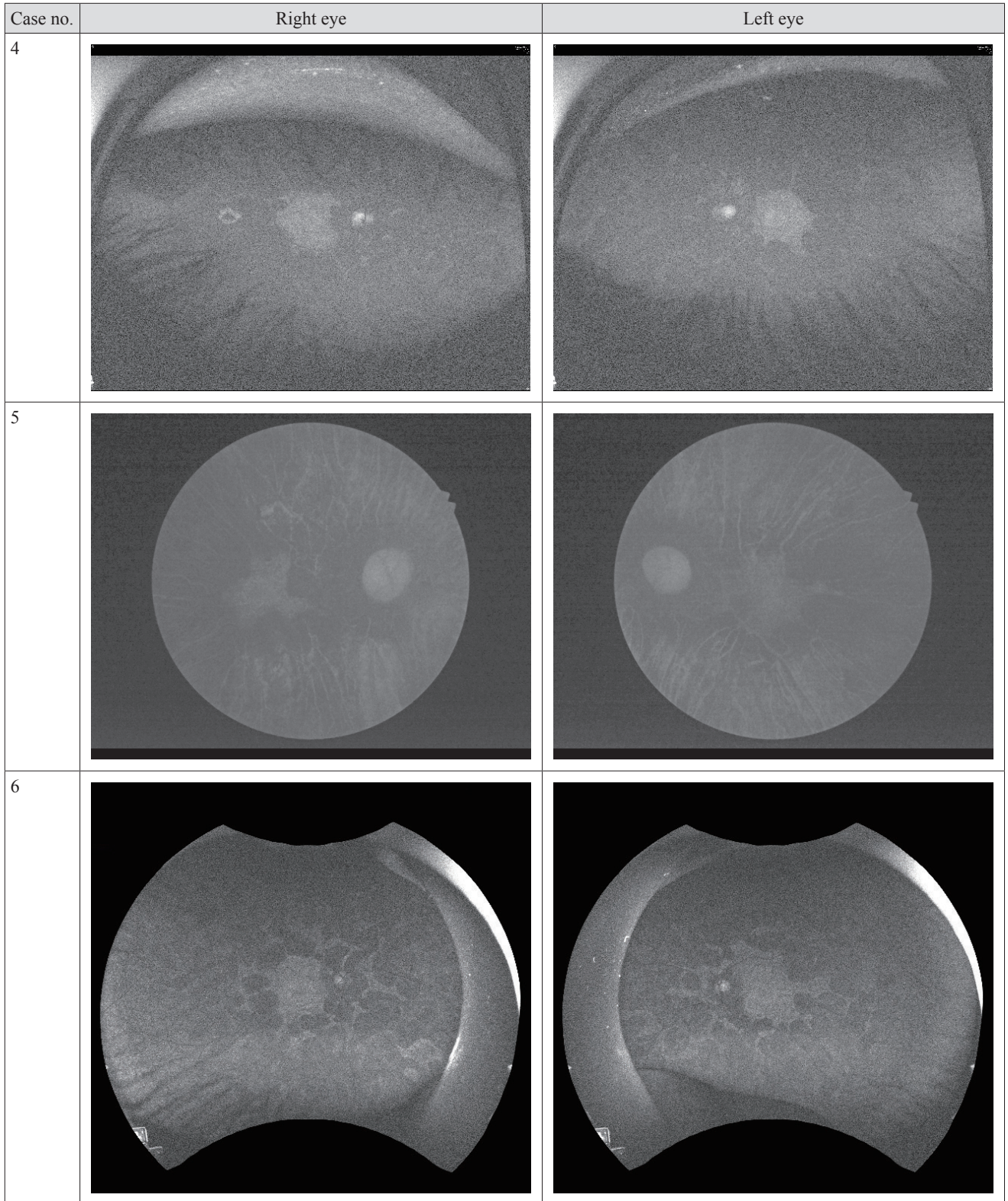
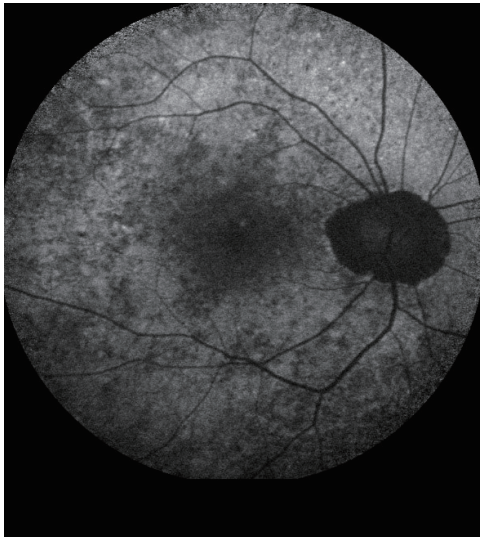

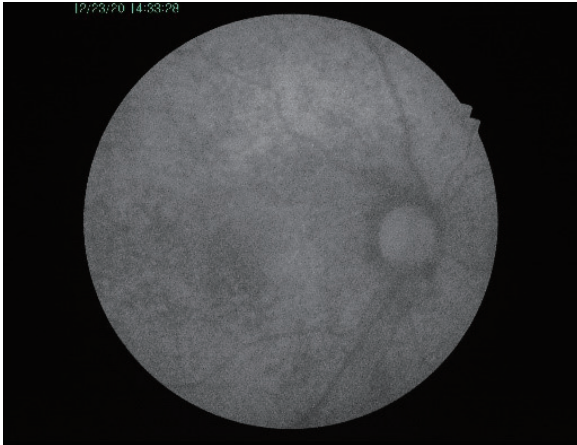
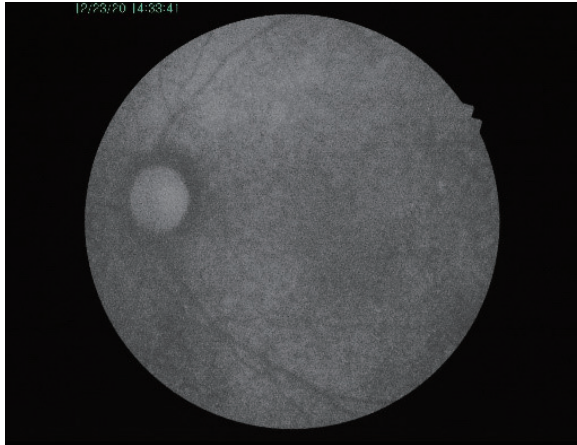
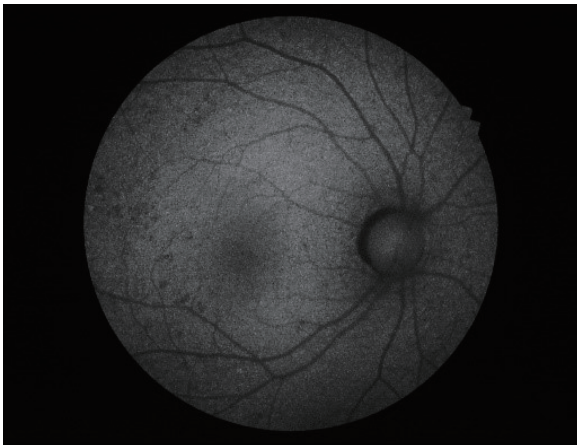
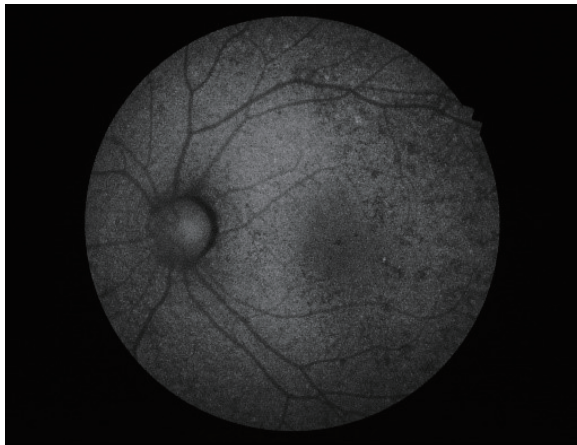


Case no.	Right eye	Left eye
1		
2		
3		

Supplementary Fig. 2. Fundus autofluorescence of six male patients with choroideremia and three female carriers.



Supplementary Fig. 2. (Continued).

Case no.	Right eye	Left eye
7		
8		
9		

Supplementary Fig. 2. (Continued).