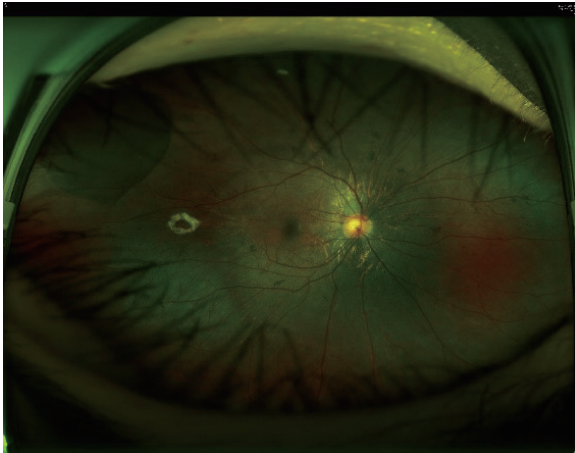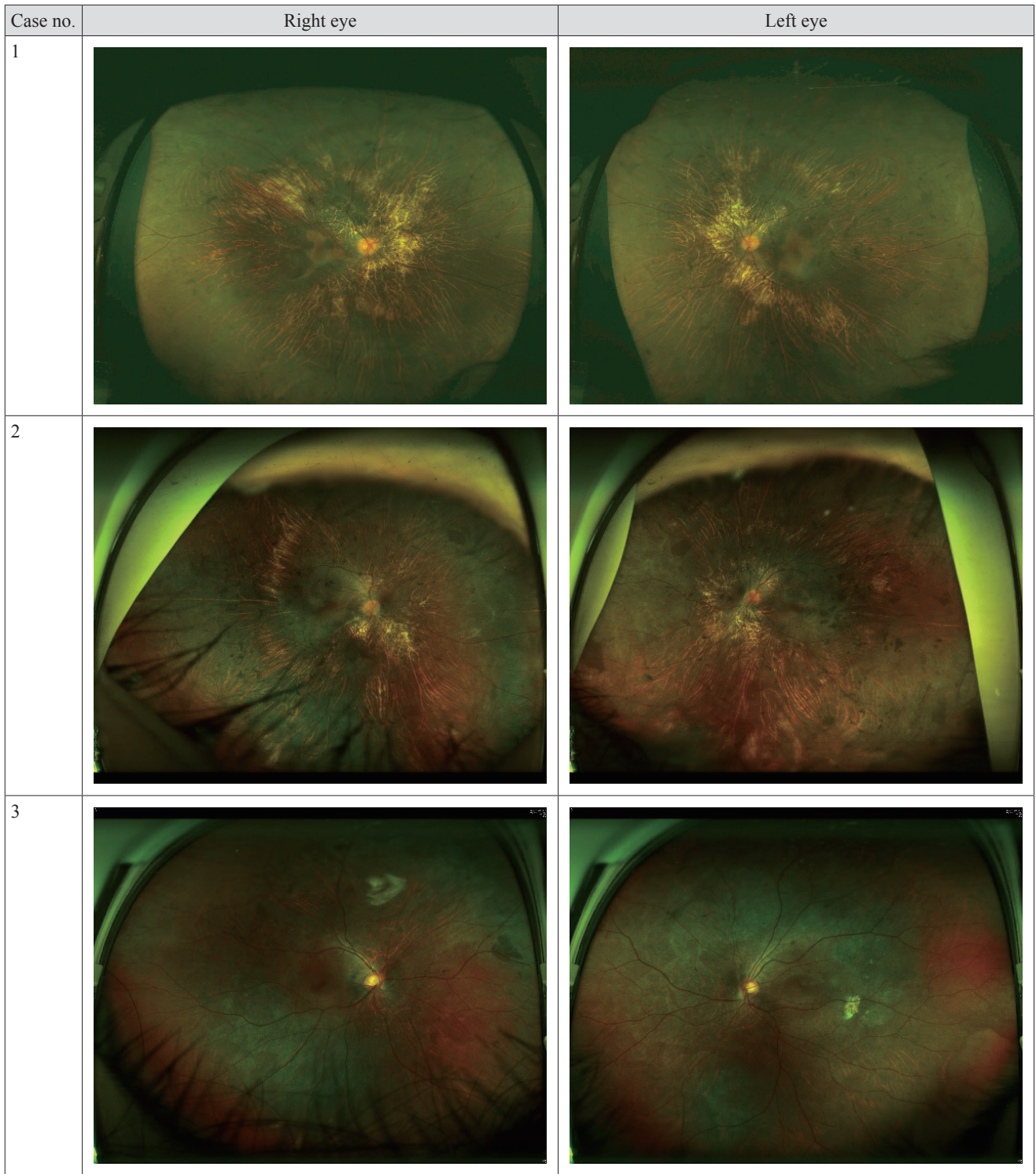
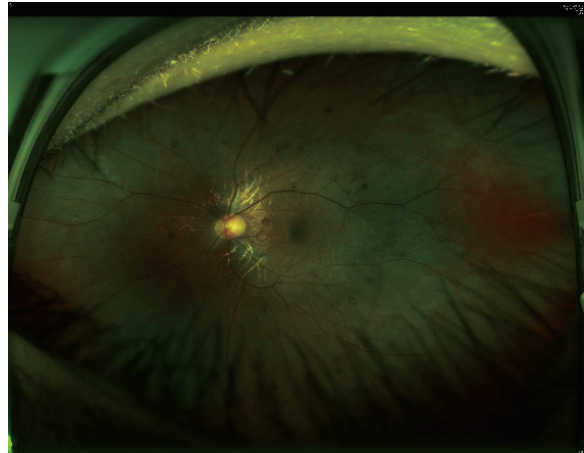
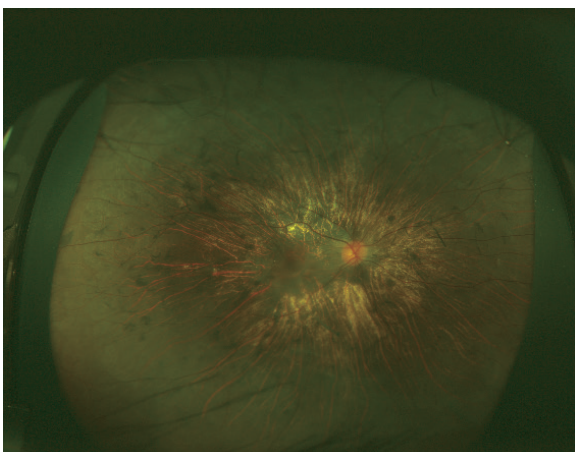
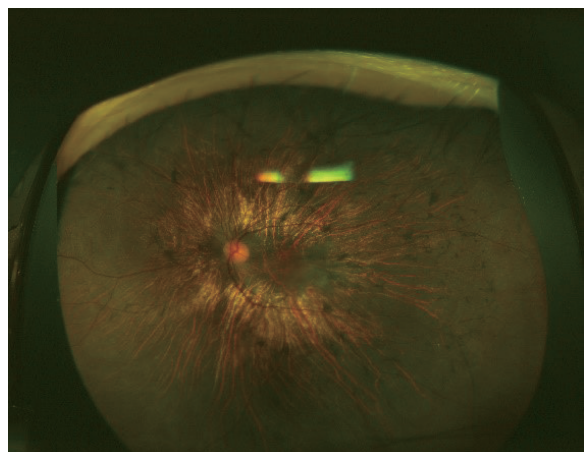
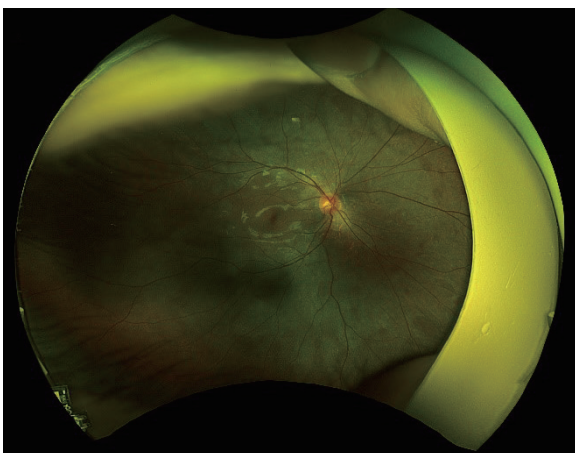
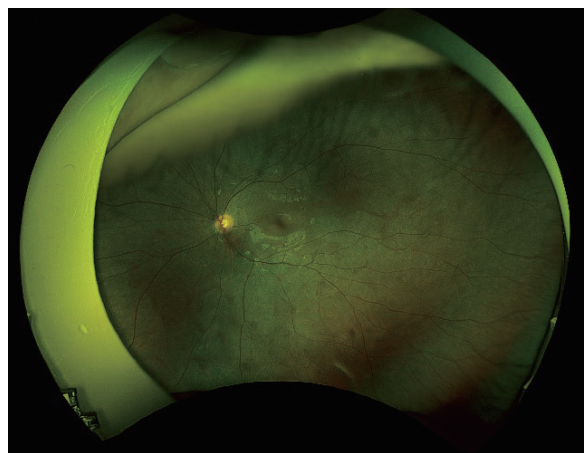
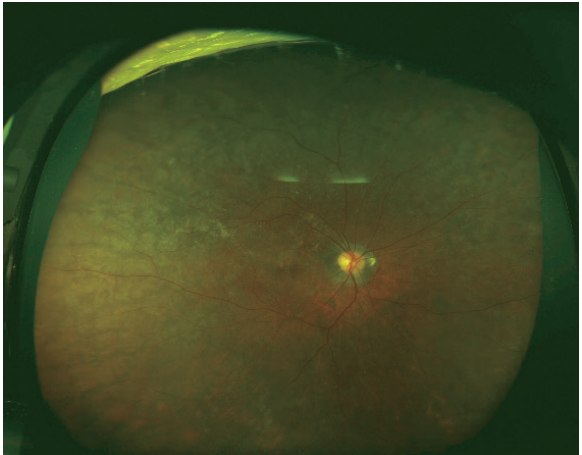
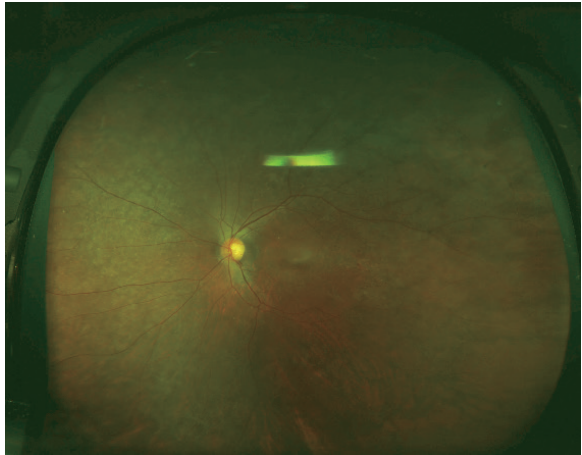
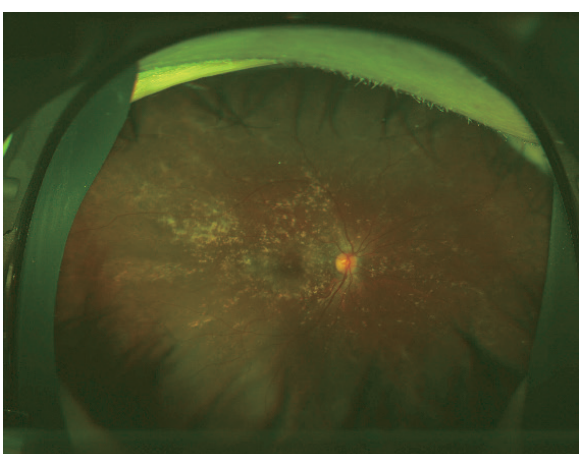
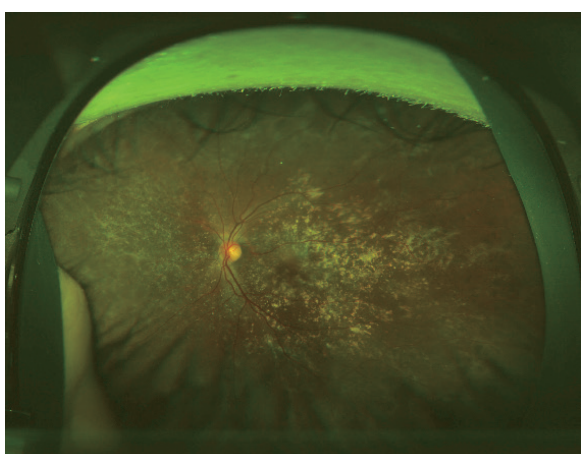
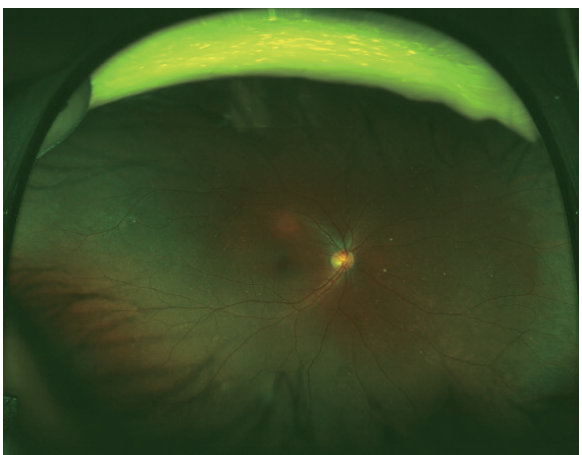
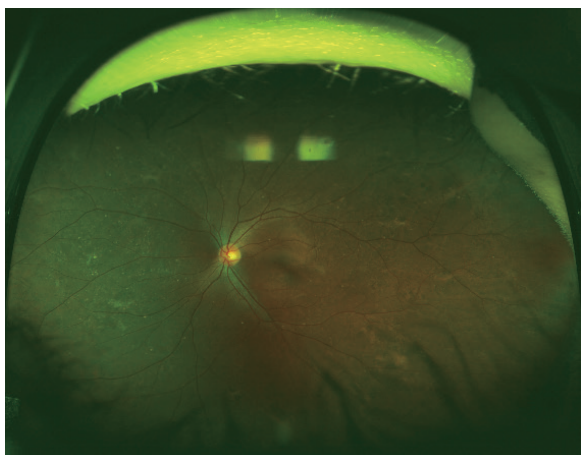


Supplementary Fig. 1. Widefield fundus photography of six male patients with choroideremia and three female carriers.

Case no.	Right eye	Left eye
4		
5		
6		

Supplementary Fig. 1. (Continued).

Case no.	Right eye	Left eye
7		
8		
9		

Supplementary Fig. 1. (Continued).